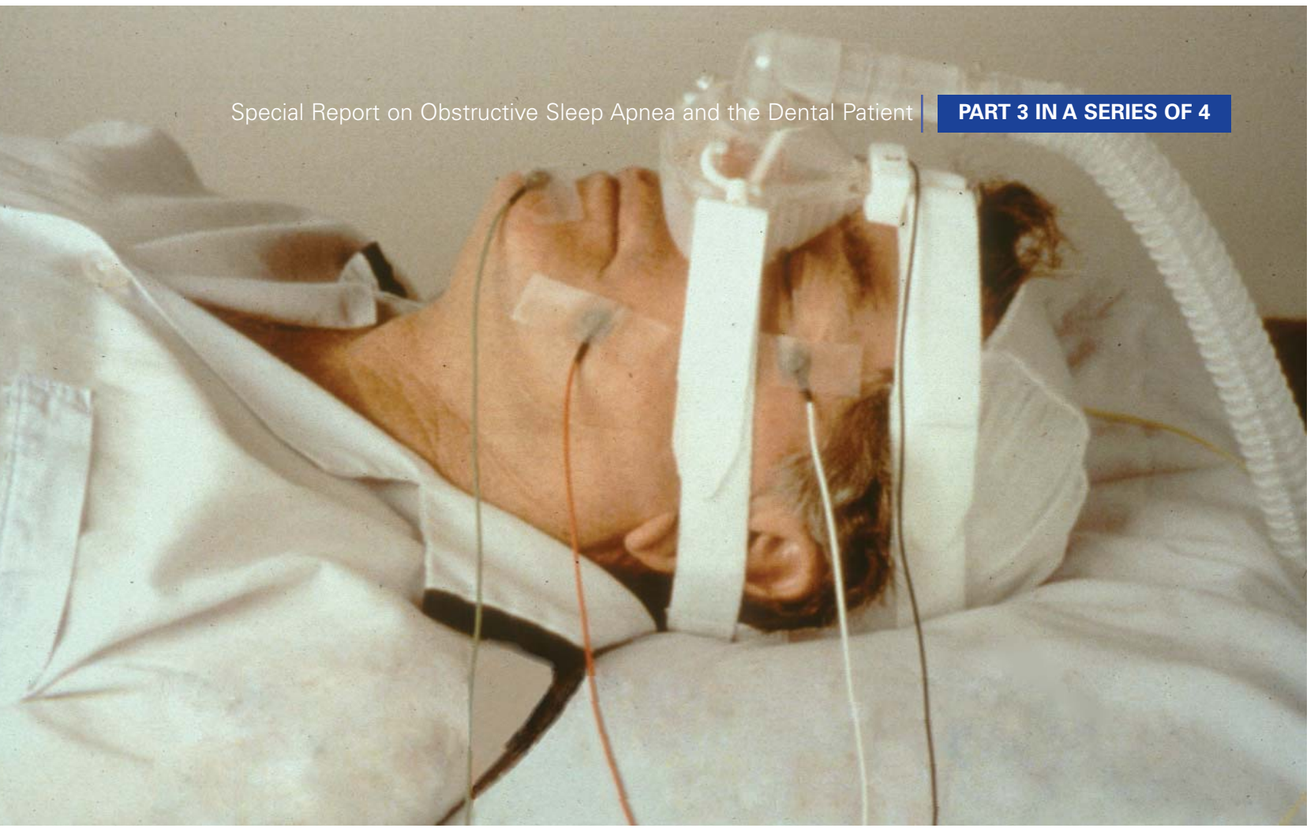

Figure 1. Example of a continuous positive airway pressure (CPAP) device during a titration polysomnogram. (Image courtesy of the American Academy of Dental Sleep Medicine.)

Therapeutic Options for Obstructive Sleep Apnea

B. GAIL DEMKO, DMD

Dr. Demko is an expert advisor on sleep apnea to the Food and Drug Administration. She maintains a private practice in Auburndale.

Editors' Note

See the first and second articles in this Special Report on obstructive sleep apnea in the Spring 2008 issue of the JOURNAL OF THE MASSACHUSETTS DENTAL SOCIETY.

Obstructive sleep apnea (OSA) could be compared to a plumbing problem. When homeowners are faced with a clogged sink drain, television advertisements tell them to buy a can of compressed air to "blow the clog away." This is effectively how continuous positive airway pressure (CPAP) treats obstructive sleep apnea. Calling the "Roto-Rooter man" will bring a plumber who will excise the offending blockage with blades on the end of a snake. This is similar to an otolaryngologist who offers a number of soft-tissue surgeries to help alleviate upper airway blockage at night. Dentists who use oral devices actually rely on the "pipe" being flexible and use devices that are effectively "pipe stretchers." Maxillofacial surgeons will use bony advancement of the lower face to alter the position of multiple muscle attachments and increase the absolute upper airway lumen. All medical treatments for OSA are mechanical therapy of a mechanical blockage; none of the present treatments actually cures OSA.

CPAP is the most effective and widely accepted therapy for OSA. It was first introduced by Colin Sullivan, MD, in 1981 when he published an article presenting clinical data about a device that used a vacuum cleaner motor to inflate the upper airway of five patients with severe sleep apnea.[1] This was the first therapy offered, other than permanent tracheotomy.

Over the last 25 years, CPAP units have gone very high-tech. They have quiet turbine blowers with electronic controls that allow them to match the patient's breathing rate rather than forcing the patient to match a pace set by the machine. Humidifiers have been added to prevent nasal drying; masks come in hundreds of sizes, materials, and styles, all to increase the patient's comfort. For patients whose symptoms are alleviated by CPAP, these machines are seen as a godsend. (See Figure 1.)

Multiple studies have been done looking at the impact CPAP has on the physical parameters of patients with OSA. CPAP improves oxygenation, decreases blood pressure, improves cardiac parameters,[2] improves insulin sensitivity,[3] minimizes daytime sleepiness, and allows severely affected patients to return to normal function. The success of CPAP in patients with mild OSA and upper airway resistance syndrome is much more controversial. Those with minor disease do not have a consistent improvement in excessive daytime sleepiness[4] and may find that CPAP interferes with their sleep as much as the breathing events do; while they may no longer snore or have oxygen desaturations, they may actually feel more tired.

CPAP is not the panacea that physicians would like patients to believe, but it is the most consistent option now available. CPAP pressures can "back pressure" sinuses, eustachian tubes, and tear ducts, or inflate the esophagus, which can cause abdominal bloating. Retrognathic patients find that the straps used to stabilize the mask often retrude the mandible, increase the retrolingual obstruction, and require higher CPAP pressure to maintain airway patency. While 90 percent of patients can be returned to normal breathing with CPAP, many patients may not be able to tolerate the treatment.[5] (See Figure 2.)

Figure 2. Use of a CPAP device with a chinstrap minimizes mouth leaks. However, compliance may be an issue with some patients.

Behavioral changes—alterations in lifestyle that the patient can initiate without medical intervention—are the least effective of all treatment modalities; this may be related to patient compliance. It is the patient who must initiate and maintain the changes, often without significant support from medical providers. Weight loss, change in sleep position (for those who show a decided propensity for breathing events in a supine position), avoidance of alcohol, smoking cessation, routine bedtimes with adequate sleep time, no shift work, and no electronic devices in the bedroom (including a clock) are often hard for patients to adopt.[6]

Surgical Treatment

Surgical treatment of OSA encompasses three aspects. For patients who are morbidly obese and dealing with metabolic syndrome, gastric bypass or lap-banding procedures have become common. The side effects can be considerable, and there are a certain proportion of patients who will redevelop OSA regardless of maintaining the postsurgical weight loss.[7] Otolaryngologists have developed more than eight soft-tissue surgeries to address various sites of upper airway obstruction and symptom complaints of patients. The American Academy of Sleep Medicine recommends approximately half of these surgeries for the treatment of OSA, but accepts all of them for the treatment of snoring. The surgeries include removal of the uvula, the caudal aspect of the soft palate, as well as the tonsils. (See Figure 3.) The attachment of the genioglossus muscle can be advanced, the hyoid moved forward, or the base of the tongue resected.

Figure 3. Throat form, post-UPPP surgery.

The surgical definition of success has, in the past, been to reduce the number of breathing events by half and to bring the total number below 20 per hour. This means that the patient may still have moderate OSA. If surgical outcomes were based on the same criteria of clinical success as are those for CPAP (fewer than five breathing events per hour), the success rate of soft-tissue surgery would be approximately 13 percent.[8] Various upper airway surgeries negatively impact future CPAP use due to an increased incidence of mouth leak. Maxillofacial surgeons now use variations on conventional maxillomandibular advancement (MMA). Correctly termed "telegnathic surgery," the patient no longer needs to have a skeletal abnormality to benefit from advancement of his or her lower face. This form of surgery is clinically successful in approximately 75 percent of the patients treated. The drawback to surgical treatment, as with others, is that effectiveness decreases with time[9] and patients must be aware that, in years to come, they may have to face CPAP as an ultimate treatment.

For children with OSA, adenotonsillectomies are the recommended surgical approach, but it should be noted that this form of surgery is less effective in African American children and children who are obese.[10] Rapid palatal expansion, nonextraction orthodontics, and functional appliance therapy may help prevent adult onset OSA in children who have malocclusions or a strong family history of OSA. (See Figures 4 and 5.)

Figure 4. A narrow palate constricts the tongue space and the floor of the mouth.

Figure 5. Photograph illustrating rapid palatal expansion.

Figure 6. A display of mandibular repositioning devices commonly used in the treatment of obstructive sleep apnea.

Mandibular Repositioning Devices

Dentists now join the ranks of surgeons and physicians in providing medical treatment for a medically recognized disease. The most common form of oral device is one that advances the mandible. All of the mandibular repositioning devices (MRDs) fulfill two criteria: they hold the mandible forward in relation to the maxilla, and they minimize vertical repositioning of the mandible. (See Figure 6.) The desired outcome is to give the body of the tongue more space to move out of the airway, to increase upper airway size, and to reduce compliance in the walls of the upper airway. Since the genioglossus (gg) muscle is attached at the tubercles in the anterior aspect of the mandible, advancing the mandible will put traction on the gg and bodily move the tongue forward. The palatoglossus muscle, which makes up the anterior pillars of the soft palate and inserts into the lateral aspect of the tongue, may transfer tension to the soft palate and help decrease snoring.

Researchers have found that when an MRD is in place, the most significant alteration in airway size is in a lateral aspect behind the soft palate.[11] The most likely explanation appears to be the small connective tissue fibers that run from the internal aspect of the rami to the lateral walls of the upper airway and pull laterally on the retropalatal upper airway walls as the mandible is advanced. In the published literature, alteration in vertical dimension of occlusion (VDO) does not appear to have significant impact on MRD success,[12] but those studies did not take into account the vertical overbite disparities or mandibular plane angle variations within the subject population.

The purpose of minimizing vertical repositioning of the mandible is to prevent triggering the anti–tongue biting reflex. At night, increased mandibular opening occurs as the level of sleep deepens. When the mandible begins to close, a reflex mechanism pulls the tongue posteriorly to prevent tongue biting and can increase airway narrowing. MRDs alter the topography of the upper airway and improve tongue space. They change the dynamic relationships between various anatomical structures, but research into the actual biomechanics behind this is in its infancy.

Of the more than 90 appliances available worldwide, more than 30 are accepted by the Food and Drug Administration (FDA) for the treatment of mild to moderate OSA. None of them is accepted for use in patients under the age of 18 due to the propensity for permanent mandibular advancement.

At present, all MRDs are retained by the dentition; some have used endosseous implants to anchor the devices, but implant-retained devices are not commercially available. An MRD can be a "monobloc" (nonadjustable), but the majority of MRDs allow the patient to alter the relationship between the jaws to minimize TMJ discomfort and maximize effectiveness.

A patient must have an adequate range of natural mandibular protrusive movement to be an acceptable candidate for MRD therapy. Measurement of protrusive range can be made with such devices as a George Gauge™ or a gothic arch tracer (GAT). In Sweden, researchers have used serial lateral cephalometric radiographs to determine extremes of mandibular movement. The average patient can move about 10 mm; those with condylar ankylosis may move less than 1 mm, while some may be able to move more than 21 mm. Any patient who has a mandibular protrusive range of less than 6 mm is not expected to be successful with an MRD.

There is no perfect jaw position that can be generalized to a population, but research does show that efficacy of MRD therapy is "dose dependent" on advancement: For most patients, the more the mandible is advanced, the more effective the appliance will be. Published research states that 75 percent of an individual patient's range of forward protrusion should be effective in treating that patient. It must be remembered that statistical analyses look at averages or means to help draw conclusions, but in an individual case, the patient may need to move as little as 50 percent or as much as 125 percent of his or her natural range to achieve normal breathing.

Each patient has a unique mandibular position that facilitates free nocturnal breathing; at present, the state of the art does not allow us to predict which position will be effective and each patient needs to titrate his or her mandible until the symptoms resolve. We can't even predict which patients will be successful with MRD therapy. Large statistical analyses show that only 42 percent of patients who receive an MRD will be returned to normal breathing, while 52 percent can be brought below 10 breathing events per hour.[13] Patients with severe OSA are less likely to be returned to normal breathing, while patients with minor sleep-disordered breathing are most effectively treated.

MRDs have been proven to be effective in controlling many of the sequelae of OSA. Studies have shown that not only is blood pressure reduced, but there is a reduction in naturietic hormones, excessive daytime sleepiness (EDS), and automobile accidents.[14-16]

All MRDs are variations on orthodontic appliances, such as the Herbst. However, when treating OSA, the mandible is held forward with an appliance only at night because permanent repositioning of the mandible will eventually lead to soft-tissue relapse and a need to advance further the patient's mandible for proper breathing.

Since the devices are tooth-borne, with resulting pressure on the teeth and alteration of the position of the condyle in the fossa, their use can produce side effects such as tooth movement and mobility, changes in interdental contacts, and permanent repositioning of the mandible. (See Figures 7 and 8.)

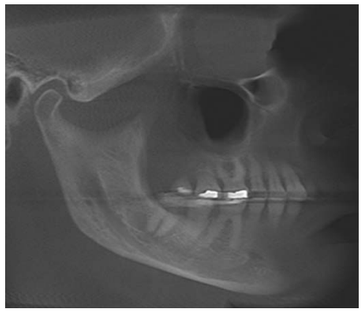

Figure 7. Condyle with no MRD in place.

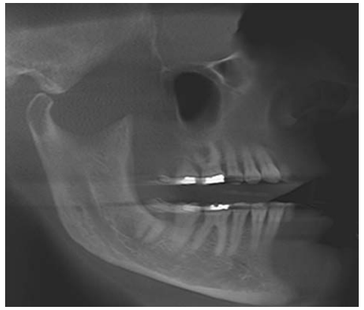

Figure 8. Condyle position with MRD in place.

Conclusion

Obstructive sleep apnea is a common medical disorder with far-reaching medical complications. Effective treatment requires a team approach among physicians, surgeons, dentists, and patients. No one therapeutic approach is guaranteed to be effective or acceptable to each patient. Lifestyle, severity of disease, treatment side effects, and patient personality all play a role in determining the appropriate treatment modality for the individual patient. Dentists are a part of the medical team, and thus it is our responsibility to offer our patients improved health and quality of life. ■

References

1. Sullivan CE, Issa FG, et al. Reversal of obstructive sleep apnoea by continuous positive airway pressure applied through the nares. Lancet. 1981;1:862-865.
2. Kaneko Y, Floras JS, Usui K, Plante J, Tkacova R, Kubo T, Ando SI, Bradley TD. Cardiovascular effects of continuous positive airway pressure in patients with heart failure and obstructive sleep apnea. N Engl J Med. 2003;348(13):1233-1241.
3. Harsch IA, et al. Continuous positive airway pressure treatment rapidly improves insulin sensitivity in patients with obstructive sleep apnea syndrome. Am J Respir Crit Care Med. 2003;169(2):156-162
4. Barnes M, et al. A randomized controlled trial of continuous positive airway pressure in mild obstructive sleep apnea. Am J Respir Crit Care Med. 2002;165:773-780.
5. Iber C. Pathophysiology and medical treatment of OSA. AADSM introductory course. Lecture; Clearwater, FL. 2008 Feb.
6. Morgenthaler TI, et al. Practice parameters for the medical therapy of obstructive sleep apnea. Sleep. 2006;29(8):1031-1034.
7. Pillar G, Peled R, Lavie P. Recurrence of sleep apnea without concomitant weight increase 7.5 years after weight reduction surgery. Chest. 1994;106(6):1702-1704.
8. Elshaug A, Moss J, Southcott AM, Hiller J. Redefining success in airway surgery for obstructive sleep apnea: a meta-analysis and synthesis of evidence. Sleep. 2007;30(4):461-470.
9. Eggensperger N, Smolka K, Johner A, Rahal A, Thüer U, Iizuka T. Long-term changes of hyoid bone and pharyngeal airway size following advancement of the mandible. Oral Surg Oral Med Oral Path Oral Radiol Endod. 2005;99(4):404-410.
10. Mitchell RB, Kelly J. Outcome of adenotonsillectomy for obstructive sleep apnea in obese and normal-weight children. Otolaryngol Head Neck Surg. 2007 Jul;137(1):43-48.
11. Ryan C, Love L, Peat D, Fleetham J, Lowe A. Mandibular advancement oral appliance therapy for obstructive sleep apnoea; effect on awake caliber of velopharynx. Thorax. 1999;54(11):972-977.
12. Pitsis AJ, Darendeliler MA, Gotsopoulos H, Petocz P, Cistulli P. Effect of vertical dimension on efficacy of oral appliance therapy in obstructive sleep apnea. Am J Respir Crit Care Med. 2002;166:860-864.
13. Ferguson K, Cartwright R, Rogers R, Schmidt-Nowara W. Oral appliances for snoring and obstructive sleep apnea: a review. Sleep. 2006;29(2):244-262.
14. Otsuka R, Ribeiro de Almeida F, Lowe AA, Linden W, Ryan F. The effect of oral appliance therapy on blood pressure in patients with obstructive sleep apnea. Sleep Breath. 2006;10(1):29-36.
15. Hoekema A, Stegenga B, Bakker M, Brouwer W, Bont L, Wijkstra P, Hoeven J. Simulated driving in obstructive sleep apnoea-hypopnoea; effects of oral appliances and continuous positive airway pressure therapy. Sleep Breath. 2007;11(3):129-138.
16. Hoekema A, Stel A, Stegenga B, van der Hoeven J, Wijkstra P, van Driel M, de Bont L. Sexual function and obstructive sleep apnoea-hypopnoea; a randomized clinical trial evaluating the effects of oral-appliance and continuous positive airway pressure therapy. J Sex Med. 2007;4(4 Pt 2):1153-1162.